Cover Page
DOI: http://ijmer.in.doi./2021/10.06.154

INTERNATIONAL JOURNAL OF MULTIDISCIPLINARY EDUCATIONAL RESEARCH
ISSN:2277-7881; IMPACT FACTOR :7.816(2021); IC VALUE:5.16; ISI VALUE:2.286
Peer Reviewed and Refereed Journal: VOLUME:10, ISSUE:6(8), June:2021
Online Copy of Article Publication Available: www.ijmer.in
Digital certificate of publication:http://ijmer.in/pdf/e-Certificate%20of%20Publication-IJMER.pdf
Scopus Review ID: A2B96D3ACF3FEA2A
Article Received: 10th June - Publication Date:30th June 2021

STEROID SWORD ENGENDERS TUBERCULOSIS STORM - A CASE REPORT

Dr Mohamed Rafi Kathar Hussain
Assistant Professor
Department of Radio Diagnosis, Sri ManukulaVinayagar Medical College
Kalitheerthalkuppam, Puducherry, India

ABSTRACT

Background: The association of long-term steroid intake for any autoimmune disorder in precipitating tuberculosis is still controversial. Disseminated tuberculosis is spread of infection to various parts of the body through blood or lymph system.

Case presentation: A 53-year-old female with history of intake of steroids for rheumatoid arthritis presented with loss of appetite. On ultrasound ascites with omental thickening and fibroid in the right lateral wall of uterus noted. Contrast enhanced computed tomogrpahyabdomen showed marked peritoneal enhancement, ascites with omental thickening noted. Multiple necrotic lymph nodes noted in the pre/para-aortic, precaval, retrocaval, inguinal, femoral and left axillary region. Left breast also showed a nodule in the lower inner quadrant with no spiculation. Miliary nodules seen diffusely scattered in bilateral lung fields.

Conclusion: Unchecked use of prolonged steroids lead to disseminated tuberculosis which cause significant morbidity and mortality if it is not diagnosed early.

KEYWORDS: Disseminated tuberculosis, Steroid intake and rheumatoid arthritis.

KEYMESSAGE: Prolonged unchecked use of steroid can lead to increase in the intensity of tuberculosis which doesn't present with significant clinical feature and can lead to disseminated tuberculosis.

INTRODUCTION

BACKGROUND

The role of intake of long-term steroid therapy for any autoimmune disease or collagen vascular disease in precipitating tuberculosis or in exacerbation of active or apparently inactive tuberculosis is still controversial in literature[1]. Disseminated tuberculosis is an infection which have spread from the lungs to other parts of the body through the blood or lymph system[2]We are presenting a case of disseminated tuberculosis in a patient with chronic intake of corticosteroids for rheumatoid arthritis.

CASE PRESENTATION

A 53-year-old female who is a known case of rheumatoid arthritis on corticosteroids presented with abdominal distension and loss of appetite. On examination respiratory system, cardiovascular system and abdomen were within normal limits. Multiple lymph nodes were palpable in the left axilla.

Past history of left breast nodule was noted which was treated conservatively. Then the patient was referred to our department for contrast enhanced computed tomography(CECT). No history of contact with tuberculosis in the family.

The findings noted on CECTabdomen, thorax and ultrasound of the abdomen were suggestive of,

Peritoneal tuberculosis: Moderate ascites seen in ultrasound [Figure 1]. Diffuse smooth peritoneal enhancement with no mural nodules noted in CECT [Figure 2a, b].

Omental tuberculosis: Mild edematous thickening of omentum was noted with no evidence of caking or nodules on both ultrasound and CECT abdomen [Figure 3].

Lymphnodal tuberculosis: Multiple varying sized necrotic lymph nodes noted in the pre/paraaortic [Figure 4], pre-caval, retrocaval[Figure 5]and in the left axillary region [Figure 6] and in the right femoral region [Figure 7], largest measuring 3.9 x 3.7 cm in short axis in left para-aortic region. Lymph nodes were conglomerated together.

Breast tuberculosis: A well-defined nodule noted in the lower outer quadrant of left breast with no evidence of spiculation/ cavitation [Figure 8].

Lung parenchymal tuberculosis: Bilateral lung fields shows multiple well defined tiny miliary nodules which were randomly distributed [Figure 9 a,b]. Consolidatory foci noted in the lateral segment of right middle lobe with adjacent tree in bud opacities [Figure 10a,b].

Cover Page
DOI: http://ijmer.in.doi./2021/10.06.154
INTERNATIONAL JOURNAL OF MULTIDISCIPLINARY EDUCATIONAL RESEARCH
ISSN:2277-7881; IMPACT FACTOR :7.816(2021); IC VALUE:5.16; ISI VALUE:2.286
Peer Reviewed and Refereed Journal: VOLUME:10, ISSUE:6(8), June:2021
Online Copy of Article Publication Available: www.ijmer.in
Digital certificate of publication:http://ijmer.in/pdf/e-Certificate%20of%20Publication-IJMER.pdf
Scopus Review ID: A2B96D3ACF3FEA2A
Article Received: 10th June - Publication Date:30th June 2021

Ileocaecal junction appears normal. No evidence of abnormal bowel wall thickening and pulling up of caecum.Liver, spleen, pancreas and bilateral kidneys shows normal contrast enhancement. No focal lesions. No evidence of osseous tuberculosis.

On ultrasound, uterus shows myometrial lesion in the right lateral wall of size 6.1 x 5 cm which shows heterogeneous enhancement on CECT, suggestive of uterine fibroid [Figure 11a, b]. No evidence of adnexal lesion. Bilateral ovaries appear normal [Figure 12a, b].

Later, Fine needle aspiration cytology was done from left axillary lymph nodes which shows granulomatous lymphadenitis. Final diagnosis is miliary tuberculosis, omental, peritoneal, mammary and multiple lymph nodal tuberculosis.

DISCUSSION

Tuberculosis is caused by Mycobacterium tuberculosis, which is primarily confined to lungs. It can affect any organ system, particularly in immunocompromised individuals. The order of extrapulmonary manifestation are lymphatic, genitourinary, bone and joint, miliary, meningeal tuberculosis and abdominal tuberculosis [3].

Disseminated tuberculosis is spread of infection to various parts of the body through blood or lymphatic system[2]. The pathogenesis of disseminated tuberculosis is considered to be inflammatory reaction to mycobacteria which can cause tissue damage and necrosis leading to organ dysfunction.

It is said that the anti-inflammatory properties of corticosteroids have been used to moderate these unwanted inflammatory reactions. At the same time corticosteroids have an immunosuppressive effect, and therefore treatment with corticosteroids might facilitate infection with M. tuberculosis or reactivate earlier clinical or subclinical infection [2].

Pulmonary tuberculosis – Earliest manifestation is poorly defined patchy consolidation in the apical and posterior segment of upper lobe. Cavitation is the hallmark manifestation of post primary tuberculosis. Tree in bud opacities indicate the endobronchial spread of infection. Pleural extent of infection manifest as pleural effusion, pleural thickening and calcification [4].

Tuberculous lymphadenopathy– Nodes at any region greater than 2 cm in diameter having central necrosis at CT which is highly suggestive of active disease.CT is more sensitive modality of investigation for assessing lymphadenopathy[5].

Abdominal tuberculosis– Peritoneal tuberculosis is the most common manifestation which usually presents as ascites and shows post contrastsmoothenhancement on CECT. Omental thickening is seen as caking, smudging or thickening. Gastrointestinal tuberculosis usually presents as concentric mural wall thickening, commonly involving ileocaecal region [6].

Genitourinary tuberculosis – Renal involvement is usually unilateral commonly presents as renal calcification which is appreciated on CT.The earliest abnormality is a “moth-eaten” calyx due to erosions seen on intravenous urography. Wall thickening is most commonly seen involving the distal ureter causing multiple strictures and bladder usually presents as reduced volume with wall thickening and filling defects known as thimble bladder seen on both intravenous urography and CT [7]. Genital tuberculosis usually affects fallopian tube causing commonly bilateral salphingitis[8].

The long-term use of steroid therapy for any autoimmune disorder, collagen vascular disorder or even for interstitial lung disease is seen to precipitate or exacerbate active or apparently inactive tuberculosis [9].

Lesson learnt from this case report is prolonged use of steroid can lead to increase in the intensity of tuberculosis which doesn’t present with significant clinical feature. Steroid act as a two-edge sword, on one side it is used as a treatment of complicated tuberculosis and on the other side unchecked use of prolonged steroids lead to disseminated tuberculosis which causes significant morbidity and mortality if not diagnosed early [10].

Conclusion: Unchecked use of prolonged steroids lead to disseminated tuberculosis which cause significant morbidity and mortality if it is not diagnosed early.

ABBREVIATIONS

1. CECT - contrast enhanced computed tomography
2. CT- Computed tomography

Cover Page
DOI: http://ijmer.in.doi./2021/10.06.154

INTERNATIONAL JOURNAL OF MULTIDISCIPLINARY EDUCATIONAL RESEARCH
ISSN:2277-7881; IMPACT FACTOR :7.816(2021); IC VALUE:5.16; ISI VALUE:2.286
Peer Reviewed and Refereed Journal: VOLUME:10, ISSUE:6(8), June:2021
Online Copy of Article Publication Available: www.ijmer.in
Digital certificate of publication:http://ijmer.in/pdf/e-Certificate%20of%20Publication-IJMER.pdf
Scopus Review ID: A2B96D3ACF3FEA2A
Article Received: 10th June - Publication Date:30th June 2021

REFERENCES

1. Senderovitz T, Viskum K. Corticosteroids and tuberculosis. Respiratory Medicine (1994) 88, 561-5.
2. Burrill F, Williams CF, Bain G, Conder G, Hine AL, Misra RR. Tuberculosis: A Radiologic Review. RadioGraphics 2007; 27:1255–73.
3. Khandelwal N, Chowdhury V, Gupta AK. AIIMS MAMC PGI'S Comprehensive textbook of diagnostic radiology.New Delhi: Jaypeebrothers medical publishers; 2017.
4. Andreu J, Caceres J, Pallisa E, Martinez-Rodriguez M. Radiological manifestations of pulmonary tuberculosis.Eur J Radiol 2004;51(2):139 – 49.
5. Curvo-Semedo L, Teixeira L, Caseiro-Alves F. Tuberculosis of the chest.Eur J Radiol 2005; 55(2):158 –72.
6. Leder RA, Low VH. Tuberculosis of the abdomen. RadiolClin North Am 1995; 33:691–705.
7. Engin G, Acunas B, Acunas G, Tunaci M. Imaging of extrapulmonary tuberculosis.RadioGraphics 2000;20(2):471– 88.
8. Wang LJ, Wong YC, Chen CJ, Lim KE. CT features of genitourinary tuberculosis. J ComputAssist Tomogr 1997;21(2):254 –8.
9. King EQ, Johnson JB, Batten GS, Henry WL. Report of a case of rapidly progressive pulmonary tuberculosis following cortisone therapy for rheumatoid arthritis. JAMA Sep 15, 1951.
10. Pal D, Behera D, Gupta D, Aggarwal A. Tuberculosis in patients receiving prolonged treatment with oral corticosteroids for respiratory disorders. Ind. J Tub 2002:83-5.

Cover Page
DOI: http://ijmer.in.doi./2021/10.06.154

INTERNATIONAL JOURNAL OF MULTIDISCIPLINARY EDUCATIONAL RESEARCH
ISSN:2277-7881; IMPACT FACTOR :7.816(2021); IC VALUE:5.16; ISI VALUE:2.286
Peer Reviewed and Refereed Journal: VOLUME:10, ISSUE:6(8), June:2021
Online Copy of Article Publication Available: www.ijmer.in
Digital certificate of publication:http://ijmer.in/pdf/e-Certificate%20of%20Publication-IJMER.pdf
Scopus Review ID: A2B96D3ACF3FEA2A
Article Received: 10th June - Publication Date:30th June 2021

Figure (1): Trans abdominal ultrasound shows free fluid in the abdomen.

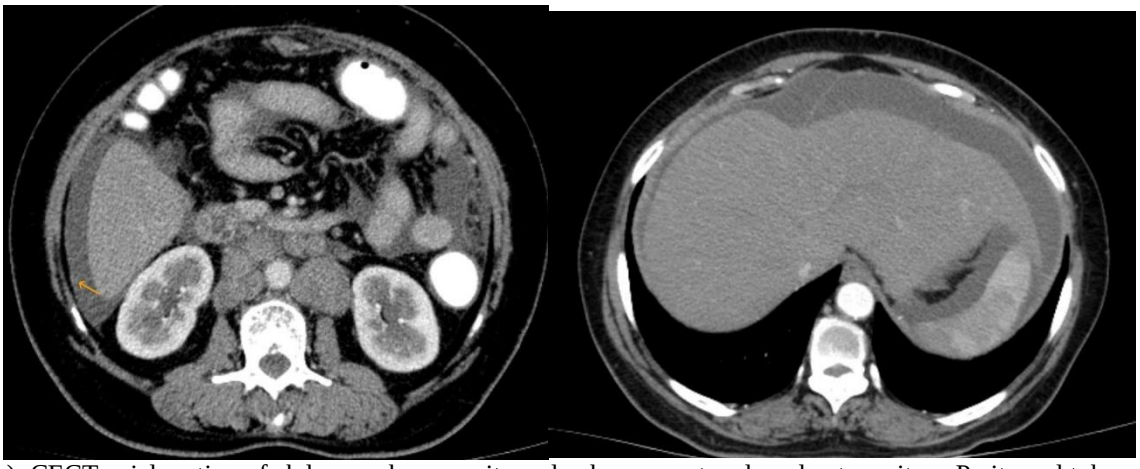

FIGURE 2(a,b): CECT axial section of abdomen shows peritoneal enhancement and moderate ascites –Peritoneal tuberculosis.

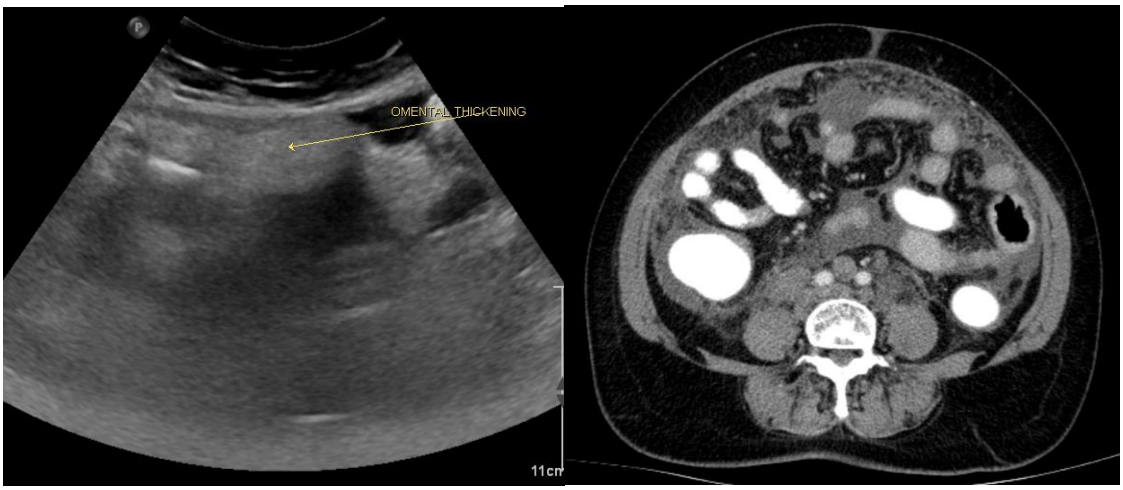

Figure (3): Transabdominal ultrasound and CECT abdomen axial section shows omental thickening and oedema. No evidence of nodules.

Cover Page
DOI: http://ijmer.in.doi./2021/10.06.154

INTERNATIONAL JOURNAL OF MULTIDISCIPLINARY EDUCATIONAL RESEARCH
ISSN:2277-7881; IMPACT FACTOR :7.816(2021); IC VALUE:5.16; ISI VALUE:2.286
Peer Reviewed and Refereed Journal: VOLUME:10, ISSUE:6(8), June:2021
Online Copy of Article Publication Available: www.ijmer.in
Digital certificate of publication:http://ijmer.in/pdf/e-Certificate%20of%20Publication-IJMER.pdf
Scopus Review ID: A2B96D3ACF3FEA2A
Article Received: 10th June - Publication Date:30th June 2021

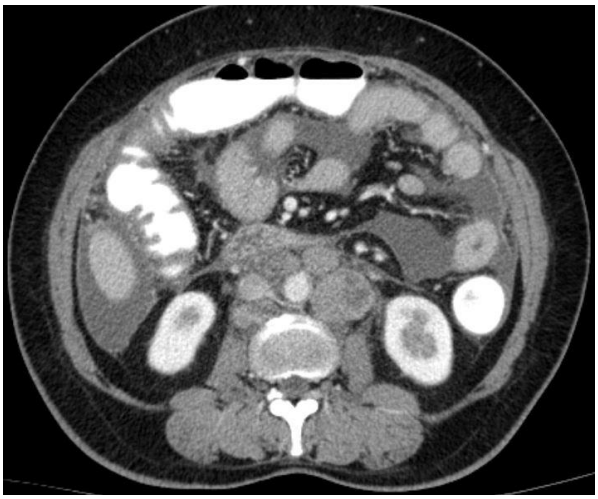

Figure (4): CECT abdomen axial section shows multiple para and pre aortic lymph nodes with central non-enhancement suggestive of necrosis.

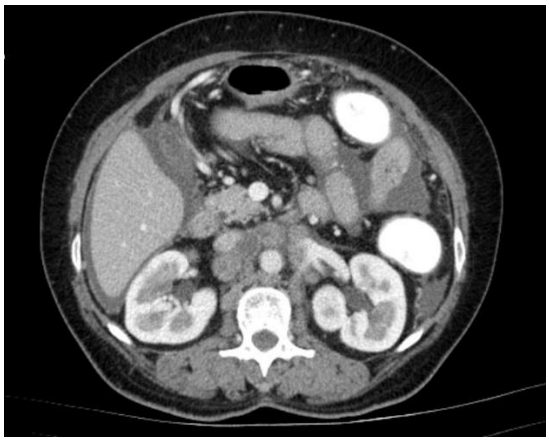

Figure (5): CECT abdomen axial section shows multiple precaval, retrocaval lymph nodes seen to push the inferior vena cava anteriorly.

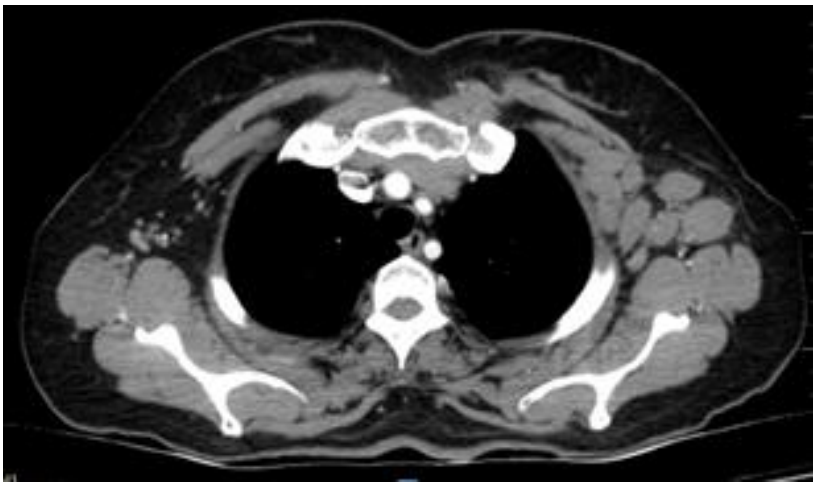

Figure (6): CECT axial section of thorax, shows multiple left axillary enlarged lymph nodes.

Cover Page
DOI: http://ijmer.in.doi./2021/10.06.154

INTERNATIONAL JOURNAL OF MULTIDISCIPLINARY EDUCATIONAL RESEARCH
ISSN:2277-7881; IMPACT FACTOR :7.816(2021); IC VALUE:5.16; ISI VALUE:2.286
Peer Reviewed and Refereed Journal: VOLUME:10, ISSUE:6(8), June:2021
Online Copy of Article Publication Available: www.ijmer.in
Digital certificate of publication:http://ijmer.in/pdf/e-Certificate%20of%20Publication-IJMER.pdf
Scopus Review ID: A2B96D3ACF3FEA2A
Article Received: 10th June - Publication Date:30th June 2021

Figure (7): CECT abdomen axial section shows multiple right femoral lymph nodes.

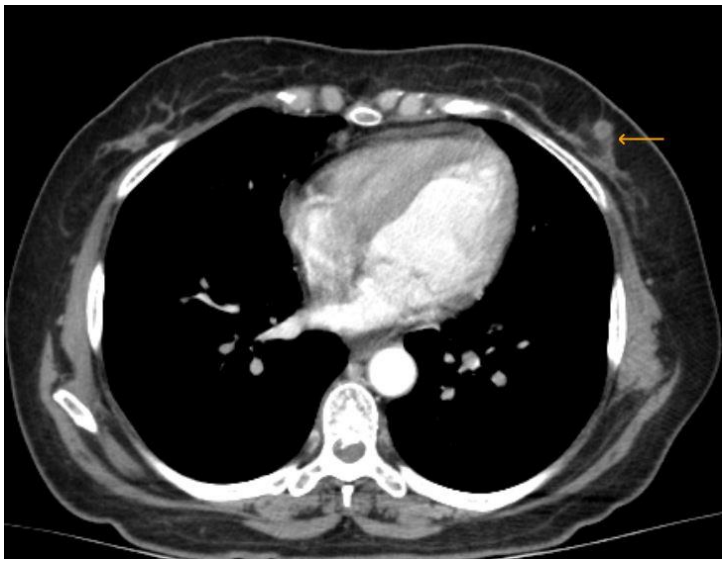

Figure (8): CECT thorax axial section shows a well-defined non enhancing nodule in the lower inner quadrant of left breast.

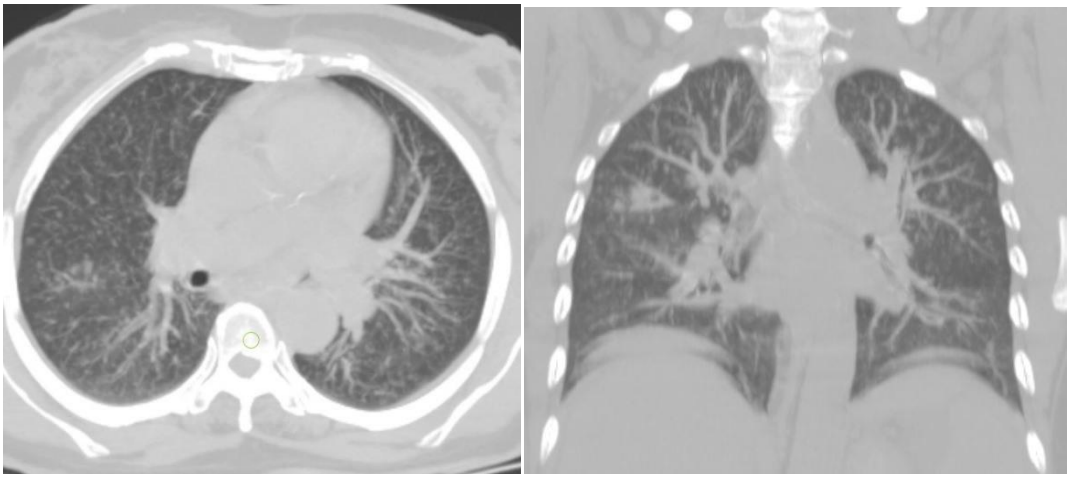

Figure (9a, b): Axial and coronal reformatted section of thorax shows randomly distributed miliary nodules – suggestive of miliary tuberculosis.

Cover Page
DOI: http://ijmer.in.doi./2021/10.06.154

INTERNATIONAL JOURNAL OF MULTIDISCIPLINARY EDUCATIONAL RESEARCH
ISSN:2277-7881; IMPACT FACTOR :7.816(2021); IC VALUE:5.16; ISI VALUE:2.286
Peer Reviewed and Refereed Journal: VOLUME:10, ISSUE:6(8), June:2021
Online Copy of Article Publication Available: www.ijmer.in
Digital certificate of publication:http://ijmer.in/pdf/e-Certificate%20of%20Publication-IJMER.pdf
Scopus Review ID: A2B96D3ACF3FEA2A
Article Received: 10th June - Publication Date:30th June 2021

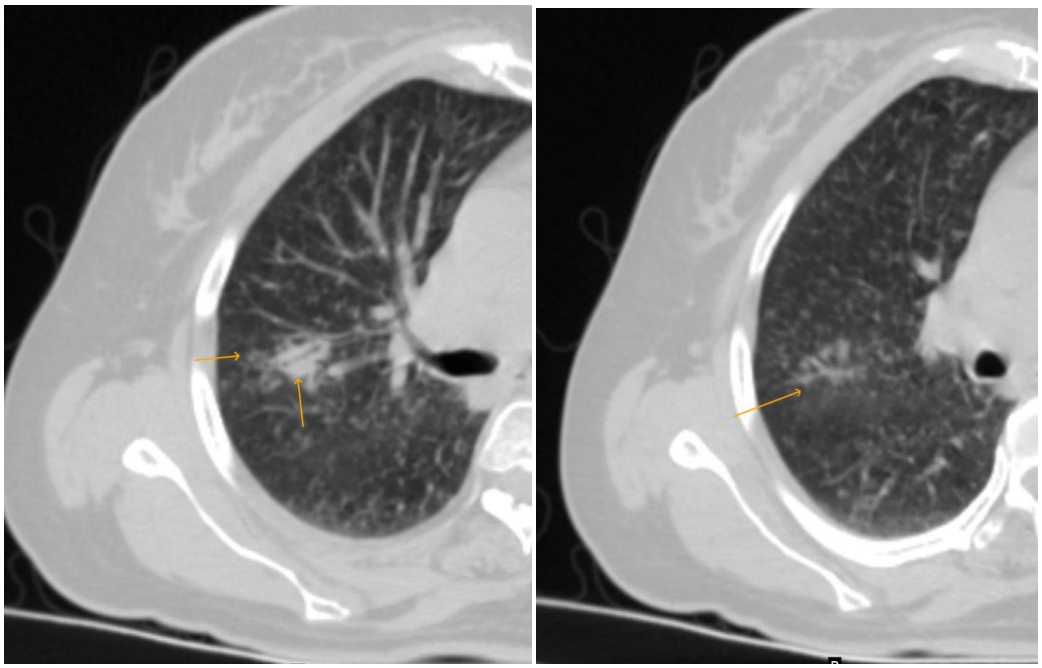

Figure (10 a,b): Axial section of thorax lung window shows consolidatory foci in the lateral segement of right middle lobe with adjacent tree in bud opacity (marked in arrow).

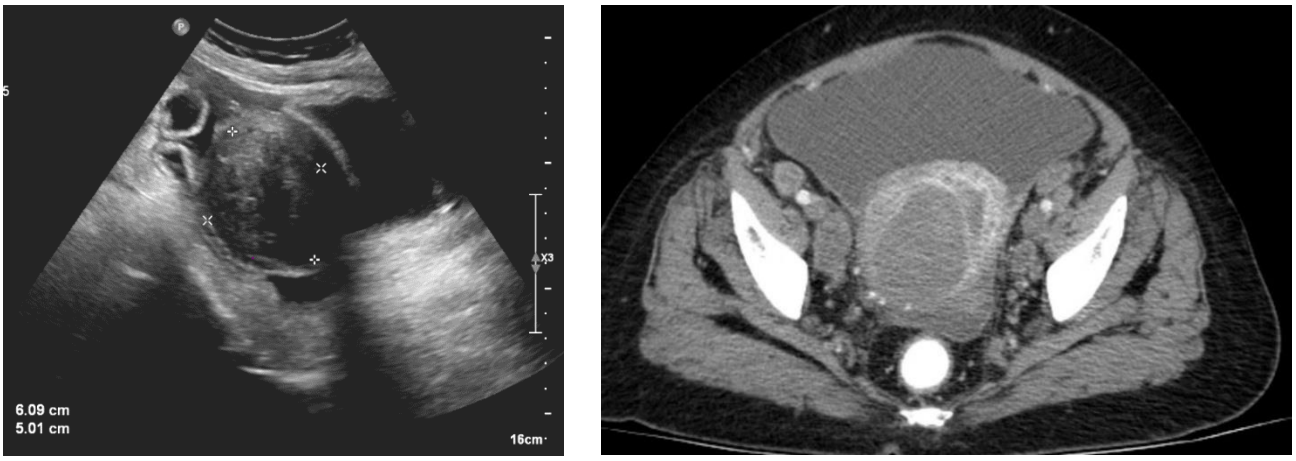

Figure (11a, b): Transabdominal ultrasound and CECT axial section of pelvis shows peripherally enhancing myometrial lesion in the right lateral wall of uterus.

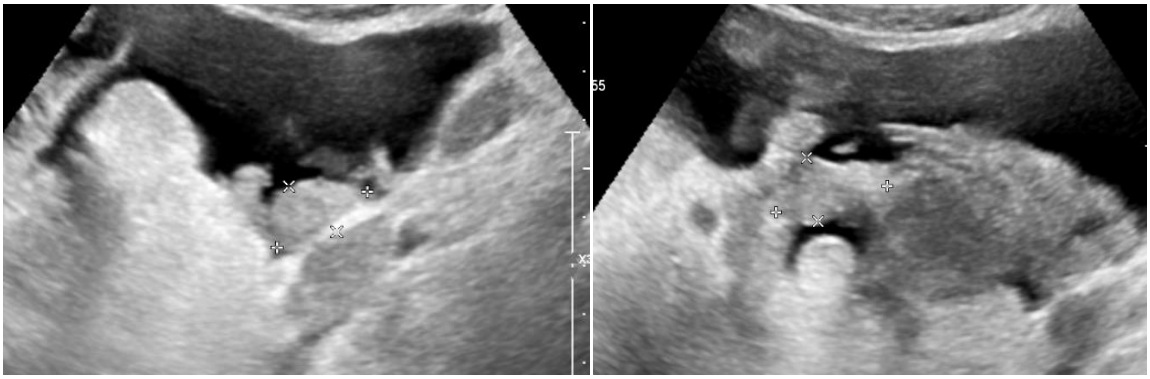

Figure (12a, b): Transabdominal ultrasound shows right and left ovary with no evidence of adnexal mass lesion.